

PATIENT

Charlie Karamat

PRESENTING CLINICAL SIGNS

History: Acute onset of seizures. H/O addisons. Bradycardia noted during the echo (largely nsf).

SPECIES

Canine

HOLTER MONITOR FINDINGS AND RHYTHM ASSESSMENT

BREED

Cockapoo

Time analyzed	23:58h
Mean heart rate	107bpm
Maximum heart rate	234bpm
Minimum heart rate	66bpm
VPCs	0
APCs	0

SEX

Male Neutered

Interpretation: Underlying normal sinus rhythm with presumably appropriate rate variation (no diary included). Max heart rate is sinus in origin. No extended pauses, escape beats or AV block noted.

AGE

5 y

Rhythm diagnosis: Sinus rhythm.

WEIGHT

22lbs

RECOMMENDATIONS

Apparently normal recording. No significant pauses are noted, and no malignant arrhythmias identified. The max HR appears sinus in origin, without obvious SVT or VT.

These findings would suggest a neurologic origin of the episodes is likely, as no structural disease or arrhythmic disease have been identified.

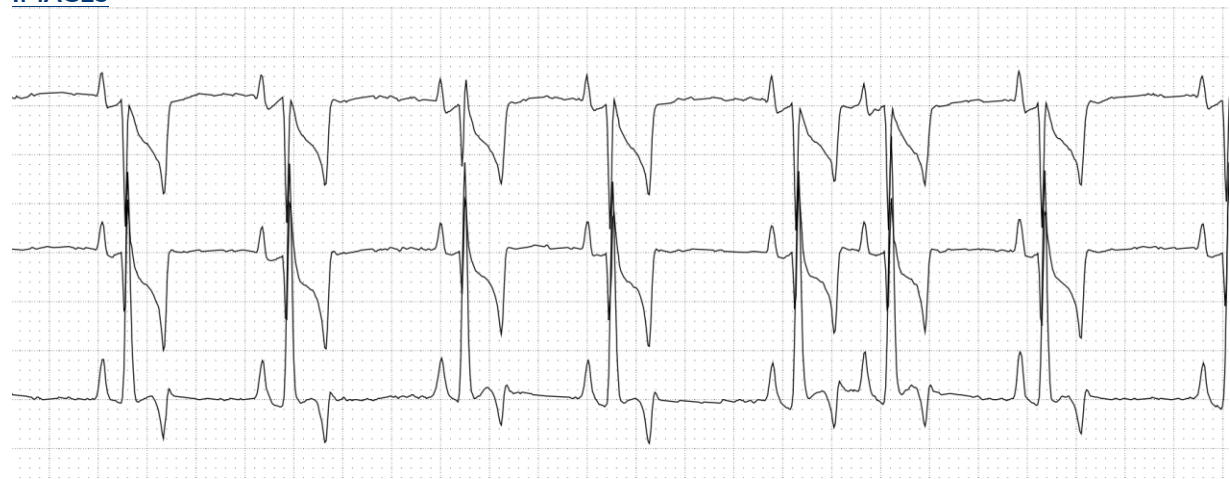INTERPRETED BY

No medications are indicated at this time.

Maggie Machen Lamy,
DVM, DACVIM
(Cardiology)

IMAGES

IMAGING PERFORMED BY



HOSPITAL NAME

Rockaway AH

REFERRING VET

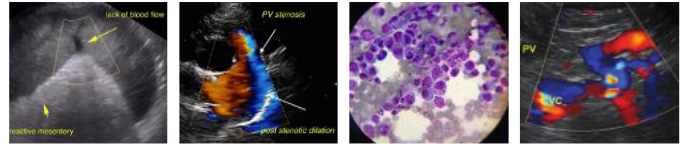
Dr. Maniar

INVOICE

31369

DATE

6/15/23



PATIENT

Charlie Karamat

SPECIES

Canine

BREED

Cockapoo

SEX

Male Neutered

AGE

5 y

WEIGHT

22lbs

INTERPRETED BY

Maggie Machen Lamy,
DVM, DACVIM
(Cardiology)

IMAGING PERFORMED BY

HOSPITAL NAME

Rockaway AH

REFERRING VET

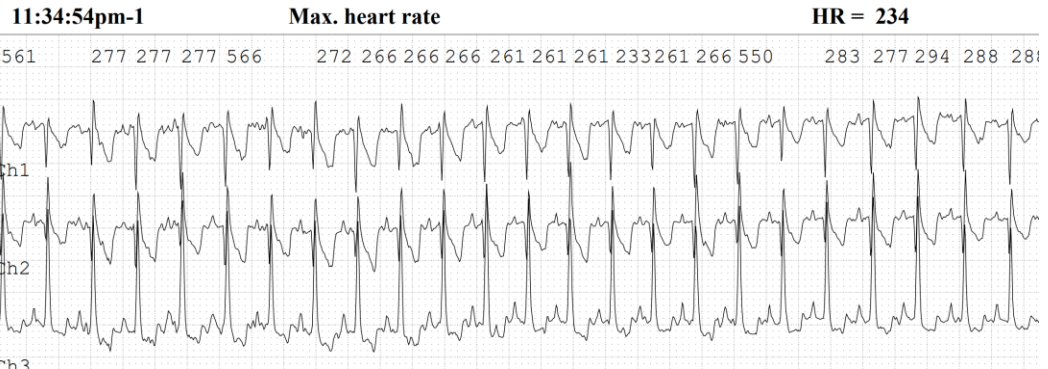
Dr. Maniar

INVOICE

31369

DATE

6/15/23



The information and recommendations provided are based on the images presented by the referring veterinarian. No evaluation can be communicated regarding pathology that was not visible in the image/video clips provided.

Thank you for this referral. If the clinical or image interpretation does not parallel your findings or if I can be of any further assistance please contact me.

Maggie Machen Lamy, DVM
Diplomate of the American College of Veterinary Internal Medicine (Cardiology)
info@sonopath.com